

Symptomatic Neural Loop Causing Hemidigital Anesthesia: Case Report

Kurt J. Hofmann, MD, David E. Ruchelsman, MD

Digital neural loops were identified over a century ago and are common findings in cadaveric studies of palmar and digital anatomy. Symptomatic digital neural loops are rare. We report a case of hemidigital anesthesia resulting from a proper digital nerve neural loop penetrated by its common digital artery in the palm. After neurolysis of the median nerve and the common and proper digital nerves to the third webspace, we transected the common digital artery, transposed it out of the neural loop, and repaired it. The patient's sensory symptoms fully resolved over 6 weeks. The differential diagnosis, diagnostic workup, and surgical treatment are reviewed. (*J Hand Surg* 2012;37A:1994–1996. Copyright © 2012 by the American Society for Surgery of the Hand. All rights reserved.)

Key words Digital artery, digital nerve, microsurgery, neural loop.

IN 1887, HARTMANN¹ described 2 variants of the neural loop. The more prevalent “buttonhole” subtype creates a 5- to 10-mm loop in length, and the “ellipse” variant creates an elongated aperture measuring approximately 8 cm in length. Hartmann reported neural loops in 67% of specimens in his initial description.

This finding was corroborated more than a century later in a cadaveric study performed by Lee and colleagues.² Those authors demonstrated neural loops in 98 of 121 cadaveric palms (81%). The researchers observed approximately 2 neural loops per hand and identified 4 topographical subtypes and 3 morphological variants. Neural loops involving peripheral nerves have also been described, including the median nerve³ and the ulnar nerve⁴ in the palm.

Etiologies of digital sensory deficits beyond peripheral nerve compression (ie, carpal tunnel syndrome, cubital tunnel syndrome, ulnar tunnel syndrome) include intrinsic and extrinsic causes of digital nerve compression. They also include intraneural masses

(ie, intraneural ganglion) or fibrosis, reactive hyperplasia of the nerve support elements,⁵ hyperplastic Pacinian corpuscles,⁶ and compressive lesions^{7,8} of the palm. De Smet⁹ reported compression of a digital nerve resulting from a tight transverse fibrous band arising from the pretendinous bands between the superficial transverse ligament and the deep transverse intermetacarpal ligament. Spinner et al¹⁰ reported posttraumatic digital neurovascular symptoms thought to result from common digital artery penetration through a proper digital nerve. Despite the high prevalence of digital neural loops, these anatomic variants are typically asymptomatic.

CASE REPORT

A 62-year-old man presented with a 3-month history of atraumatic hemidigital anesthesia on the radial side of the left ring finger. Physical examination was without provocative signs of peripheral median or ulnar nerve compression at the elbow, forearm, or wrist. There were no palpable masses in the palm or ring finger. The patient demonstrated full pain-free range of motion of the ring finger. A Tinel's sign was elicited between the proximal palmar crease and the proximal interphalangeal joint flexion crease of the ring finger with radiation of neuritic pain along the radial half of the ring finger. Static 2-point discrimination was normal (5 mm) in the ulnar digital nerve territory but greater than 15 mm in

From the Department of Orthopaedic Surgery, Tufts University School of Medicine, Boston; and the Division of Hand and Upper Extremity and Microsurgery, Newton-Wellesley Hospital, Newton, MA.

Received for publication June 21, 2012; accepted in revised form July 15, 2012.

No benefits in any form have been received or will be received related directly or indirectly to the subject of this article.

Corresponding author: David E. Ruchelsman, MD, 2000 Washington Street, Blue Building, Suite 201, Newton, MA 02462; e-mail: druchelsman@partners.org.

0363-5023/12/37A10-0006\$36.00/0
http://dx.doi.org/10.1016/j.jhssa.2012.07.012

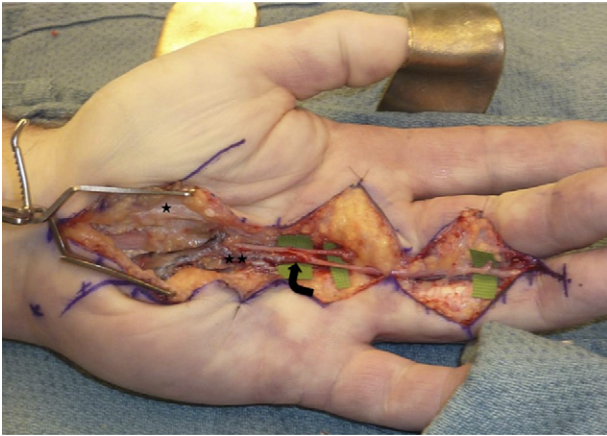


FIGURE 1: Neurolysis of the median nerve from the carpal tunnel through the common digital nerve bifurcation is complete. Common digital artery penetration of the radial digital nerve was found 25 mm distal to common digital artery takeoff from the superficial palmar arch. Single star, radial leaflet of transverse carpal ligament; double stars, third common digital artery; curved arrow, neural loop of radial digital nerve.

the radial digital nerve distribution. Two-point discrimination was 5 mm in all other fingers. Allen test revealed patent radial and ulnar arteries. There was no thenar or hypothenar muscle wasting.

Preoperative magnetic resonance imaging of the hand and digits revealed no abnormal masses. Electrodiagnostic testing, including a median-ulnar ring finger comparison study, revealed complete absence of the median sensory response within the ring finger, with a normal ulnar sensory response in the ring finger. Mild median neuropathy at the wrist was present, as indicated by mild prolongation of the distal peak sensory latency (3.75 ms) of the median-D2 sensory nerve action potential (normal median sensory peak latency is less than 3.5 ms across the wrist segment).

We performed concomitant median nerve decompression at the wrist and neurolysis of the common digital nerve to the third webspace under regional anesthesia. The median nerve did not appear compressed within the carpal tunnel. After carpal tunnel release, the superficial palmar arch and the third common digital nerve were mobilized. During neurolysis of the common digital nerve and artery to the third webspace, we identified no masses or tethering fascial bands from the proximal palmar crease to the proximal digital crease. We then neurolysed the bifurcation of the common digital nerve. At 25 mm distal to the takeoff of the third common digital artery (CDA) from the superficial palmar arch, the CDA directly penetrated the radial digital nerve to the ring finger (Fig. 1). The nerve divided in half just distal to its bifurcation from the common

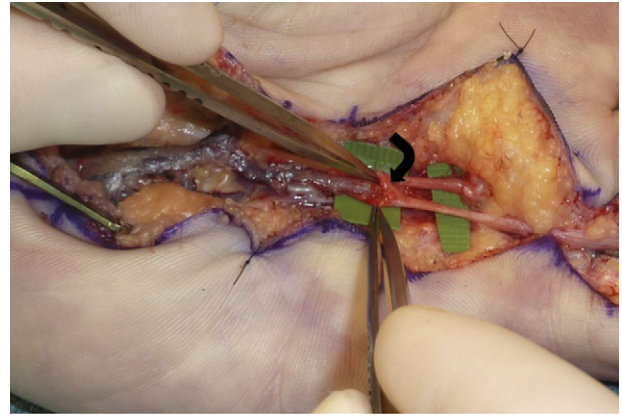


FIGURE 2: Neural loop of the radial digital nerve of the ring finger penetrated by the third common digital artery. The site of the neural loop corresponds to the site of the maximal Tinel's sign preoperatively. Curved arrow, neural loop of radial digital nerve with penetration by common digital artery.

digital nerve, forming a neural loop (Fig. 2). The ulnar digital nerve to the middle finger was not involved. Under operative microscope, we transected the CDA just proximal to the neural loop. We then performed microvascular repair after transposing the CDA volar to the digital nerves. The site of the patient's maximal Tinel's sign correlated with the site of the neural loop.

At 1 week postoperatively, the patient reported noteworthy subjective sensory improvement, and static 2-point discrimination measured 7 mm in the radial digital nerve territory of the ring finger. The Tinel's sign over the course of the radial digital nerve resolved. At 6 weeks, static 2-point discrimination measured 6 mm in the radial digital nerve territory of the ring finger.

DISCUSSION

This case represents an atraumatic symptomatic penetration of a digital nerve by a digital artery in the palm. Spinner et al¹⁰ described a similar case in 1996. In that case, symptoms developed in a delayed fashion after a crush injury. Those authors noted dynamic vascular compression of a proper digital nerve and dynamic occlusion of a common digital artery. In our case, we surmise that dynamic vascular compression of the radial digital nerve resulting from pulsatile arterial flow progressed over time to static compression at the site of the neural loop. Similar to Spinner et al, we advocate microvascular decompression of the neural loop, transposition of the artery out of the neural loop, and arterial repair.

Because this anatomic variation is common,^{1,2} it is imperative for clinicians to be aware of neural loops as a potential cause of sensory symptoms in the digits. Lee et al² noted neural loops in 81% of cadaveric palms, averaging 2 neural loops per palm. They described 4

topographical types including penetration of the ulnar and radial proper digital nerves, the common digital nerve, and a bridge between the ulnar and radial proper digital nerves. In addition, they described 3 morphological forms based on the length of the neural loop aperture (A, > 10.0 mm; B, 4.0–9.9 mm; and C, < 4.0 mm).

Preoperative workup for digital neurovascular symptoms includes electrodiagnostic testing, magnetic resonance imaging, and vascular studies when arterial or vaso-occlusive etiologies are suspected. A symptomatic neural loop is a diagnostic challenge, a diagnosis of exclusion, and rare. Hand surgeons must be aware of its existence in the palm and digits, and be prepared to consider microvascular decompression if other etiologies are absent.

REFERENCES

1. Hartmann H. Note sur l'anatomie des nerfs de la paume de la main. *Bull Mem Soc Anat Paris* 1887;62:860–864.
2. Lee JY, Kim YR, Kim JN, Choi HG, Song WC, Koh KS. Penetration of the digital nerves by the common palmar digital arteries in human cadavers. *J Hand Surg* 2010;35A:2022–2026.
3. Davlin LB, Aulicino PL, Bergfield TG. Sensory neural loop of the median nerve at the carpal tunnel. *J Hand Surg* 1991;16A:863–865.
4. Rogers MR, Bergfield TG, Aulicino PL. A neural loop of the deep motor branch of the ulnar nerve: an anatomic study. *J Hand Surg* 1991;16A:269–271.
5. Dobyns JH. Digital nerve compressions. *Hand Clin* 1992;8:359–367.
6. Calder JS, Holten I, Terenghi G, Smith RW. Digital nerve compression by hyperplastic Pacinian corpuscles: a case report and immunohistochemical study. *J Hand Surg* 1995;20B:218–221.
7. De Smet L, Bande S, Fabry G. Giant lipoma of the deep palmar space, mimicking persistent carpal tunnel syndrome. *Acta Orthop Belg* 1994;60:334–335.
8. O'Connor RL. Digital nerve compression secondary to palmar aneurysm. *Clin Orthop* 1972;83:149–150.
9. De Smet L. Compression of the common digital nerve in the palm of the hand: a case report. *J Hand Surg* 1997;22A:1047–1048.
10. Spinner RJ, Varela CD, Urbaniak JR. Digital nerve penetration by a digital artery in a patient with neurovascular symptoms: a case report. *J Hand Surg* 1996;21A:1101–1103.