

Open Reduction and Internal Fixation of Capitellar Fractures with Headless Screws

Surgical Technique

By David E. Ruchelsman, MD, Nirmal C. Tejwani, MD, Young W. Kwon, MD, PhD, and Kenneth A. Egol, MD

Investigation performed at the New York University Hospital for Joint Diseases, New York, NY

The original scientific article in which the surgical technique was presented was published in JBJS Vol. 90-A, pp. 1321-9, June 2008

ABSTRACT FROM THE ORIGINAL ARTICLE

BACKGROUND: The outcome of operatively treated capitellar fractures has not been reported frequently. The purpose of the present study was to evaluate the clinical, radiographic, and functional outcomes following open reduction and internal fixation of capitellar fractures that were treated with a uniform surgical approach in order to further define the impact on the outcome of fracture type and concomitant lateral column osseous and/or ligamentous injuries.

METHODS: A retrospective evaluation of the upper extremity database at our institution identified sixteen skeletally mature patients (mean age, 40 ± 17 years) with a closed capitellar fracture. In all cases, an extensile lateral exposure and articular fixation with buried cannulated variable-pitch headless compression screws was performed at a mean of ten days after the injury. Clinical, radiographic, and elbow-specific outcomes, including the Mayo Elbow Performance Index, were evaluated at a mean of 27 ± 19 months postoperatively.

RESULTS: Six Type-I, two Type-III, and eight Type-IV fractures were identified with use of the Bryan and Morrey classification system. Four of five ipsilateral radial head fractures occurred in association with a Type-IV fracture. The lateral collateral ligament was intact in fifteen of the sixteen elbows. Metaphyseal comminution was observed in association with five fractures (including four Type-IV fractures and one Type-III fracture). Supplemental mini-fragment screws were used for four of eight Type-IV fractures and one of two Type-III fractures. All fractures healed, and no elbow had instability or weakness. Overall, the mean ulnohumeral motion was 123° (range, 70° to 150°). Fourteen of the sixteen patients achieved a functional arc of elbow motion, and all patients had full forearm rotation. The mean Mayo Elbow Performance Index score was 92 ± 10 points, with nine excellent results, six good results, and one fair result. Patients with a Type-IV fracture had a greater magnitude of flexion contracture ($p = 0.04$), reduced terminal flexion ($p = 0.02$), and a reduced net ulnohumeral arc ($p = 0.01$). An ipsilateral radial head fracture did not appear to affect ulnohumeral motion or the functional outcome.

CONCLUSIONS: Despite the presence of greater flexion contractures at the time of follow-up in elbows with Type-IV fractures or fractures with an ipsilateral radial head fracture, good to excellent outcomes with functional ulnohumeral motion can be achieved following internal fixation of these complex fractures. Type-IV injuries may be more common than previously thought; such fractures often are associated with metaphyseal comminution or a radial head fracture and may require supplemental fixation.

LEVEL OF EVIDENCE: Therapeutic Level IV. See Instructions to Authors for a complete description of levels of evidence.

ORIGINAL ABSTRACT CITATION: "Open Reduction and Internal Fixation of Capitellar Fractures with Headless Screws" (2008;90:1321-9).

DISCLOSURE: The authors did not receive any outside funding or grants in support of their research for or preparation of this work. Neither they nor a member of their immediate families received payments or other benefits or a commitment or agreement to provide such benefits from a commercial entity.



A video supplement to this article will be available from the *Video Journal of Orthopaedics*. A video clip will be available at the JBJS web site, www.jbjs.org. The *Video Journal of Orthopaedics* can be contacted at (805) 962-3410, web site: www.vjortho.com.

INTRODUCTION

Coronal shear fractures involving the capitellum represent substantial partial articular injuries that may occur in isolation, ex-

tend medially to involve the trochlea, or occur in association with complex ipsilateral periarticular elbow trauma that includes osseous or ligamentous

injuries extending beyond the lateral column. There are several fracture classifications¹⁻⁴ (Fig. 1), and surgical exposure and hardware selection are based on the

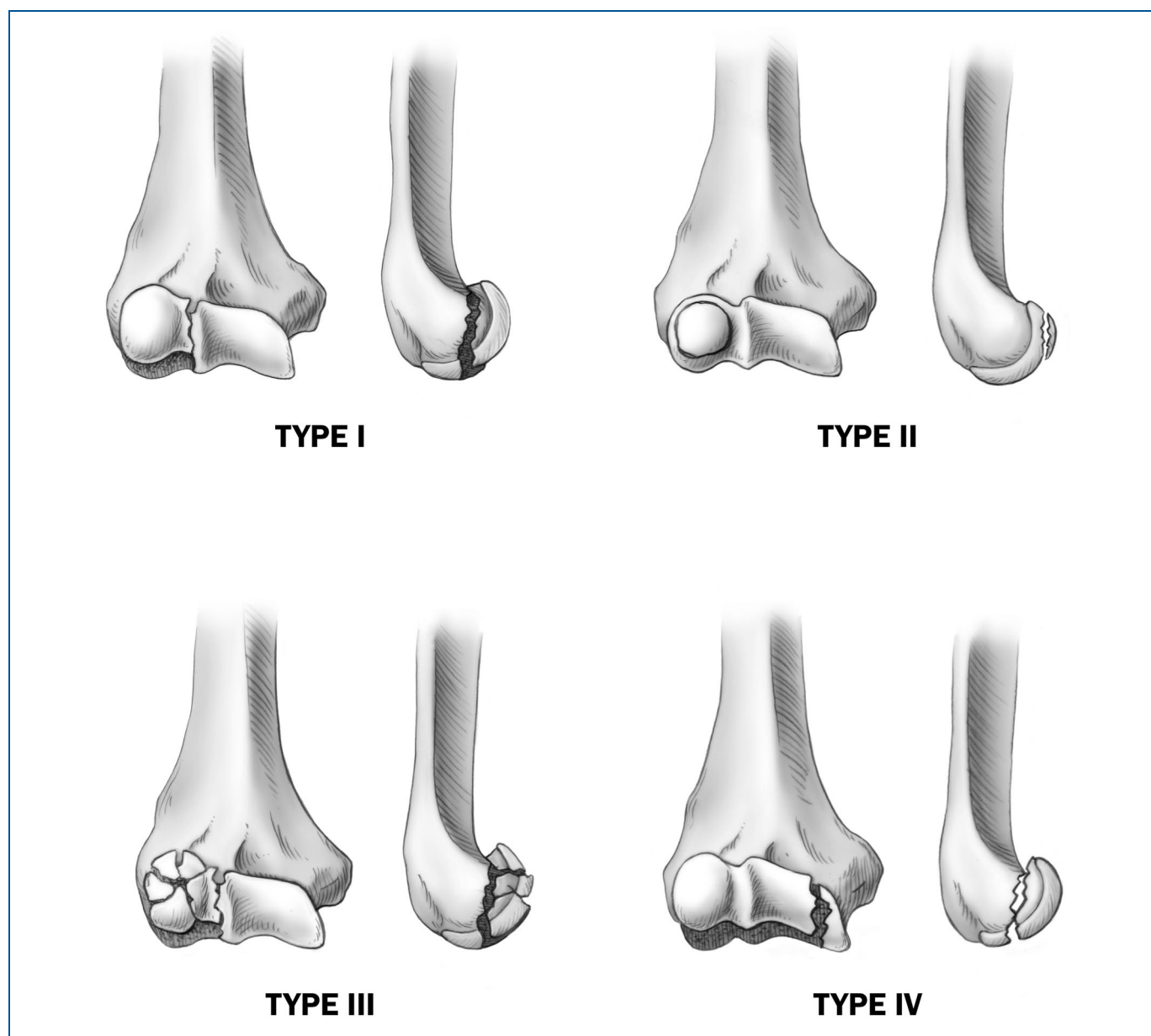


FIG. 1

The Bryan and Morrey¹ classification system. Type-I fractures are complete capitellar fractures with little or no extension into the lateral aspect of the trochlea; Type-II fractures are anterior osteochondral shear fractures with only a minimal amount of subchondral bone; Type-III fractures are comminuted or compression fractures of the capitellum; and Type-IV fractures² extend medially to include most of the trochlea. (Reprinted, with permission, from: Ruchelsman DE, Tejwani NC, Kwon YW, Egol KA. Coronal plane partial articular fractures of the distal humerus: current concepts in management. JAAOS. 2008;16:716-28.)

fracture pattern and the extent of articular involvement. As the complex nature of capitellar fractures has become better appreciated, treatment options have evolved from closed reduction and/or immobilization⁵⁻⁷ and fragment excision⁸⁻¹⁰ to a preference for open reduction and internal fixation to achieve a stable anatomic reduction in order to allow the initiation of early motion. Extensile surgical exposures and headless cannulated variable-pitch screws are

used to address more complex fracture patterns, which may be more common than previously thought. These injuries are characterized by metaphyseal comminution and ipsilateral radial head fracture, and they often require supplemental fixation¹¹. Studies on the outcomes of open reduction and internal fixation of capitellar fractures^{1-4,8,11,12-17} and associated injuries to the trochlea, radial head, and the lateral collateral ligamentous complex are lim-

ited, but they have demonstrated satisfactory functional results in the majority of patients when the injury is limited to the radiocapitellar compartment. We have utilized a uniform surgical approach for capitellar-trochlear fractures consisting of an extensile lateral exposure, articular fixation with buried cannulated variable-pitch headless compression screws, and simultaneous repair of associated osseous and ligamentous injuries.

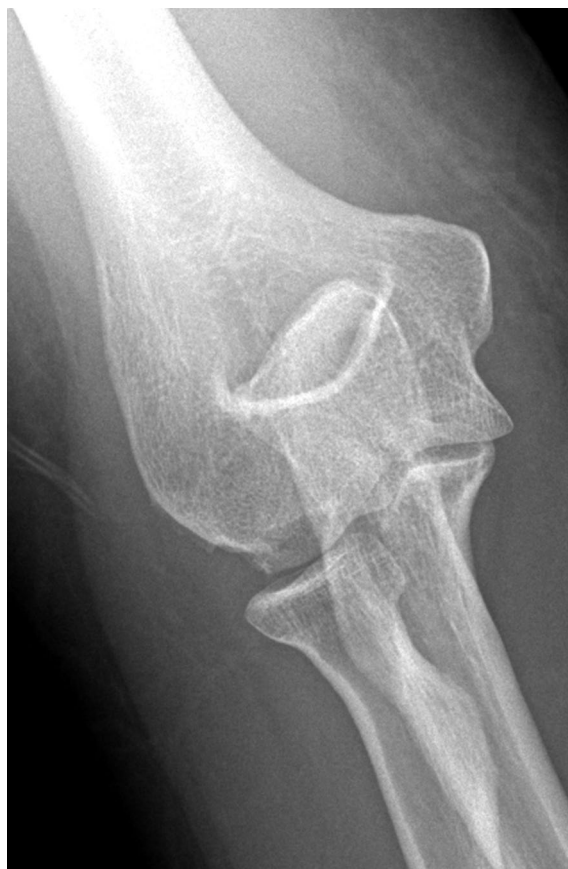

FIG. 2-A

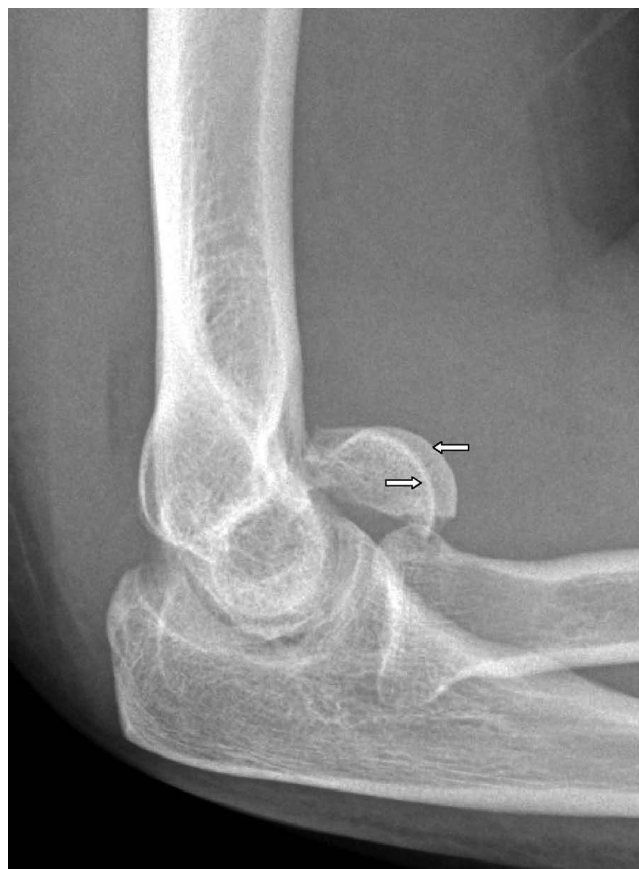

FIG. 2-B

Preoperative anteroposterior (Fig. 2-A) and lateral (Fig. 2-B) radiographs of a Type-IV capitellar fracture. The pathognomonic “double arc” sign² (arrows), representing a coronal shear fracture of the capitellum with medial extension through the trochlea, is shown. (Reprinted from: Ruchelsman DE, Tejwani NC, Kwon YW, Egol KA. Open reduction and internal fixation of capitellar fractures with headless screws. *J Bone Joint Surg Am.* 2008;90:1321-9.)

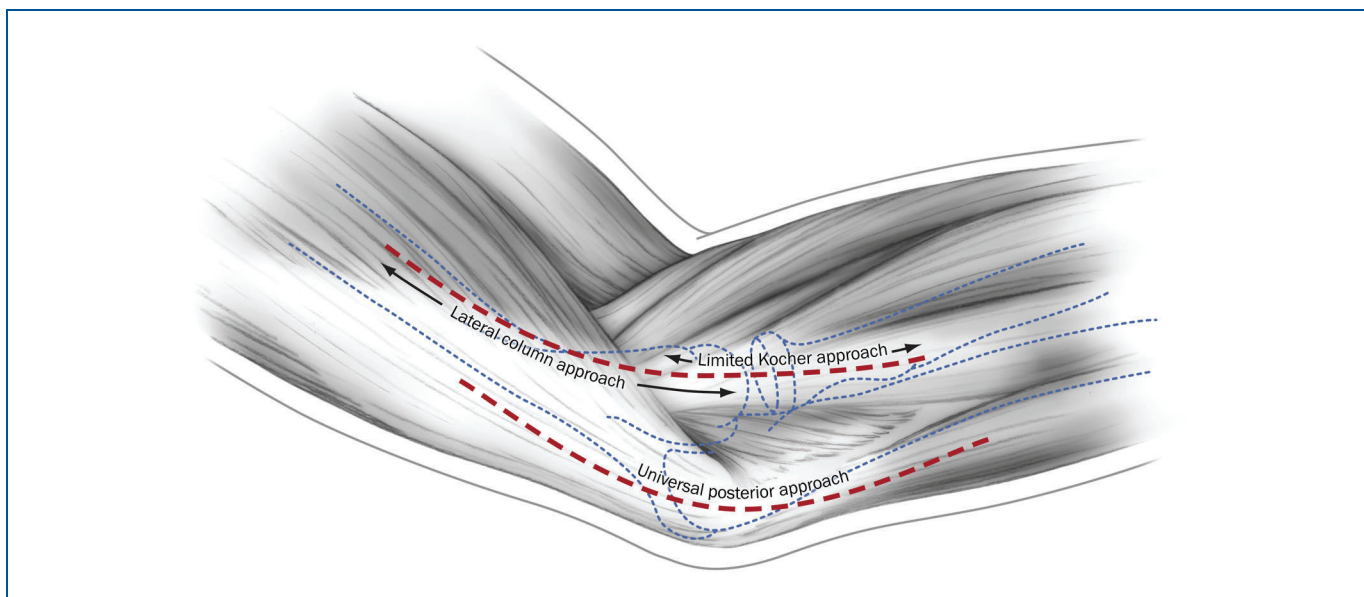


FIG. 3

Schematic representation of the surgical skin incisions available to perform an extensile lateral approach and exposure of the radiocapitellar compartment. Should the need for medial exposure (i.e., a concomitant medial epicondylar fracture, which is a Ring Type-V fracture³) or olecranon osteotomy be anticipated, a midline posterior skin incision with subsequent elevation of a full-thickness lateral skin flap is used. (Reprinted, with permission, from: Ruchelsman DE, Tejwani NC, Kwon YW, Egol KA. Coronal plane partial articular fractures of the distal humerus: current concepts in management. *JAAOS*. 2008;16:716-28.)

SURGICAL TECHNIQUE

The patient is positioned supine with the arm placed on a radiolucent hand table. Fluoroscopy is used intraoperatively to confirm reduction of the fracture. A well-padded sterile pneumatic tourniquet is applied. Following general or regional anesthesia, the injured elbow is assessed clinically for ligamentous stability.

Open reduction of capitellar-trochlear fractures (Figs. 2-A and 2-B) is performed with use of an extensile lateral exposure^{2,4,7,9,11,15,16}. A lateral skin incision (Fig. 3) at the elbow is centered over the lateral epicondyle and extends from the anterior aspect of the lateral column of the distal end of the humerus to approximately 2 cm distal to the radial head (Fig. 4-A).

Following dissection through the subcutaneous tissue layers, the lateral column is palpated (Fig. 4-B). With the forearm pronated to move the radial nerve away from the surgical field, the common origin of the radial wrist extensors in conjunction with the anterior capsule is elevated sharply as a full-thickness sleeve from the lateral supracondylar ridge anteriorly. Distally, the Kocher interval is identified and connected to the proximal exposure to develop a continuous full-thickness anterior soft-tissue flap (Fig. 4-C). With the elbow flexed, intracapsular retractors are placed deep to the brachialis and the anterior capsule and over the medial column facilitating exposure of the ante-

rior distal humeral articular fracture fragments and the radial head (Fig. 4-D). The fracture site is débrided of hematoma and soft-tissue debris to allow visualization of the fracture fragments. Retractors are not placed anterior to the radial neck to reduce the risk of an iatrogenic injury to the posterior interosseous nerve.

When posterior metaphyseal comminution is present, the lateral aspect of the triceps may also be elevated from the lateral column and the proximal ulnar metaphysis. Care is taken to preserve the lateral ulnar collateral ligament origin at the lateral epicondyle (Fig. 4-C) and the vascular supply to the capitellum. Release of the lateral ulnar collateral ligament^{2,3,11,17} is not always

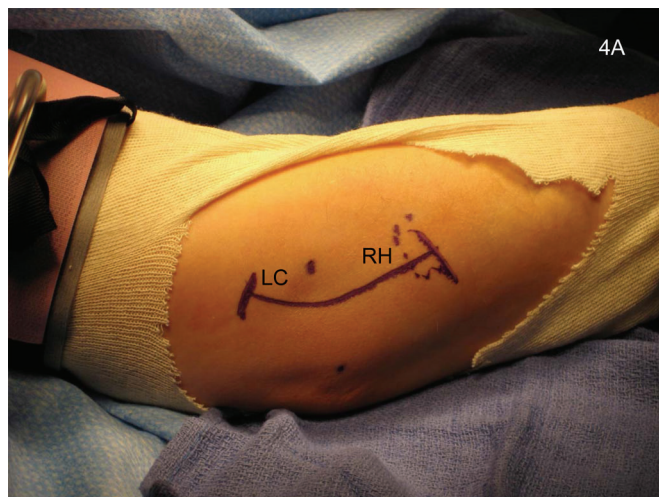


FIG. 4-A

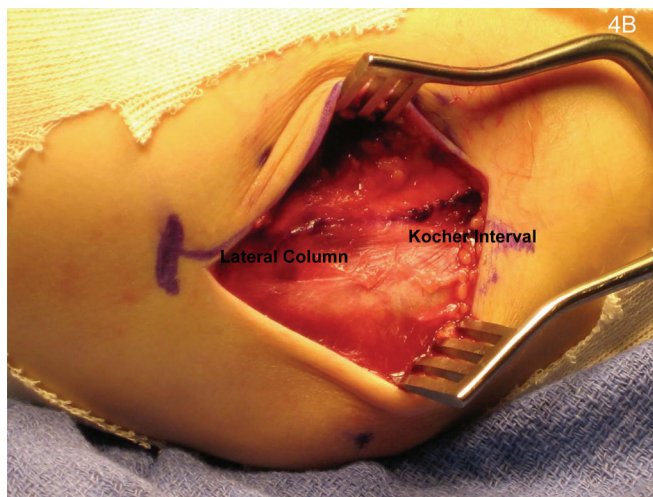


FIG. 4-B

Fig. 4-A The marked skin incision is centered over the lateral epicondyle and extends from the anterior aspect of the lateral column (LC) of the distal end of the humerus to approximately 2 cm distal to the radial head (RH). **Fig. 4-B** Dissection proceeds through the subcutaneous tissue layers, and the lateral column proximally and the Kocher interval distally are marked.

necessary even when there is trochlear extension of the coronal shear capitellar fracture. In patients with a lateral epicondylar fracture fragment (i.e., a Bryan and Morrey Type-III fracture¹; or a Ring Type-II, III, or IV fracture³), the epicondylar fracture fragment with the lateral collateral ligamentous complex origin can be reflected distally to enhance exposure^{3,11,17}. Utilizing the lateral extensile exposure does not seem to increase the risk of osteonecrosis of the capitellum or trochlea^{2,3,11,16,17}.

Anatomic reduction is directly visualized; as the articular segment is reduced along the proximal metaphyseal margin and trochlea, the capitellar fracture is provisionally fixed with a minimum of two 0.045 or 0.062-in (1.14 or 1.57-mm) Kirschner wires (Fig. 5-A). Anatomic reduction is then confirmed with

orthogonal fluoroscopy. When there is sufficient subchondral bone on the articular segment,

buried headless cannulated screws are inserted over the guidewires in an anterior-to-

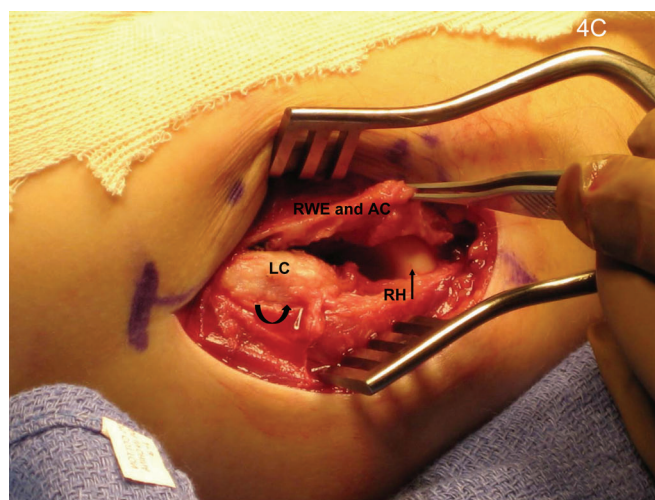
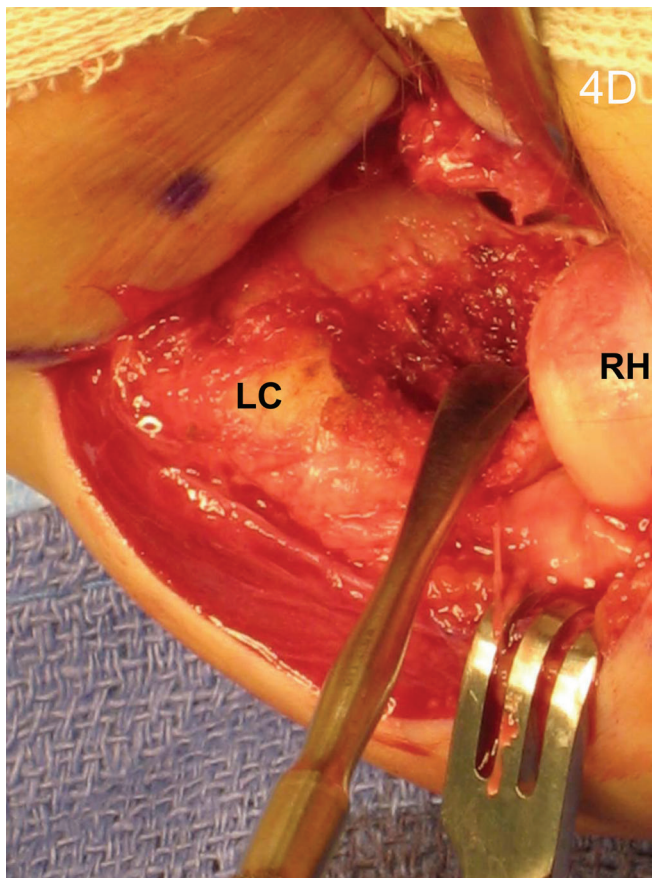
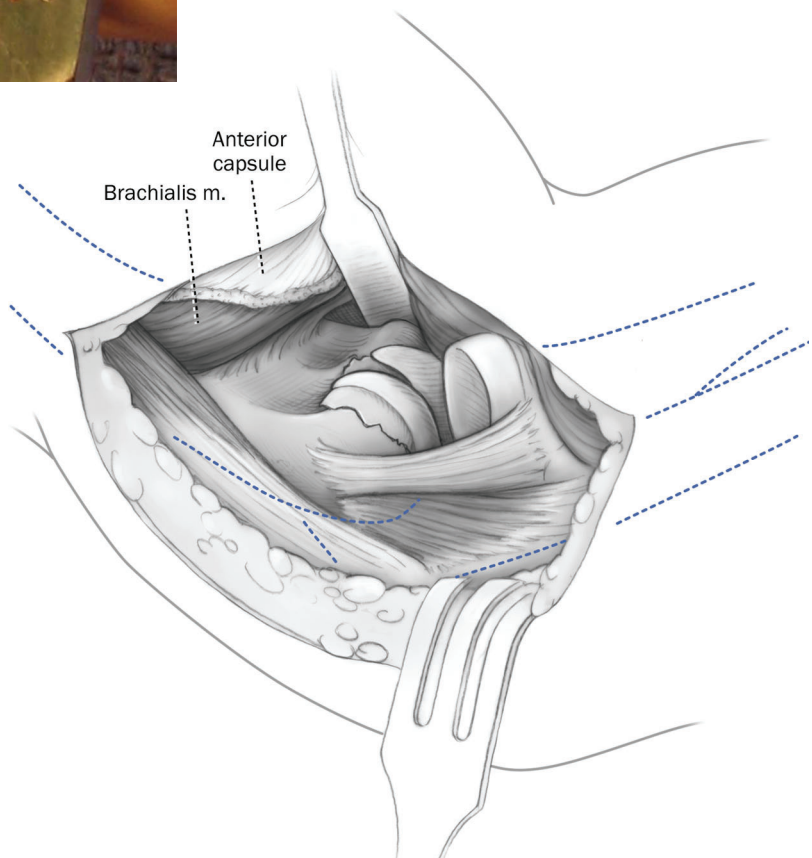


FIG. 4-C

The forearm is positioned in pronation to move the radial nerve away from the surgical field. The common origin of the radial wrist extensors (RWE) in conjunction with the anterior capsule (AC) is elevated anteriorly as a full-thickness sleeve from the lateral column (LC) supracondylar ridge and connected to the distal Kocher interval, which is used to assess the radial head (RH). The proximal and distal exposures are connected such that a continuous full-thickness anterior soft-tissue flap is developed. The lateral ulnar collateral ligament is preserved (curved arrow).

**FIG. 4-D**

The elbow is then flexed to facilitate placement of blunt Hohmann retractors deep to the brachialis and the anterior capsule and over the medial column. This facilitates maximal exposure of the anterior distal humeral articular fracture site and any associated radial head (RH) pathology. Following débridement of the fracture site, excellent visualization of the medial extent of the fracture is obtained with this exposure. Retractors placed anterior to the radial neck are avoided. The schematic shows the extensile lateral exposure. LC = lateral column. (Reprinted, with permission, from: Ruchelsman DE, Tejwani NC, Kwon YW, Egol KA. Coronal plane partial articular fractures of the distal humerus: current concepts in management. JAAOS. 2008;16:716-28.)



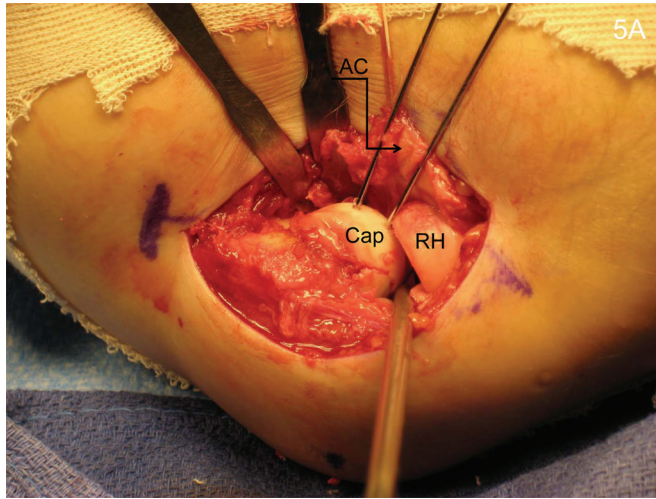


FIG. 5-A

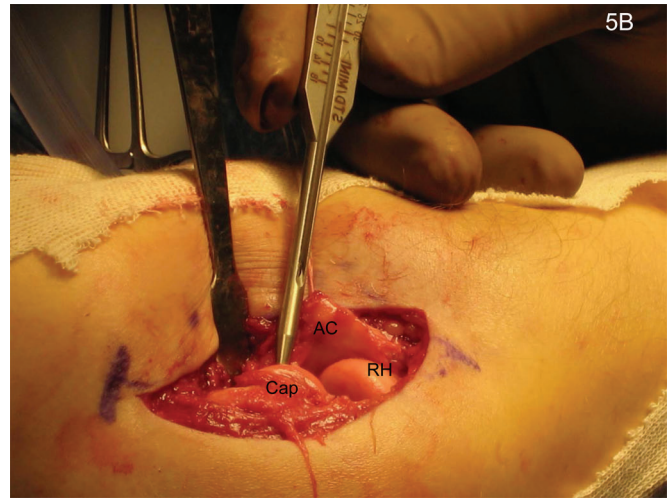


FIG. 5-B

Fig. 5-A Provisional Kirschner-wire fixation is performed following reduction of the articular keys. **Fig. 5-B** The cannulated screw lengths are measured. Cap = capitellar fracture fragment, RH = radial head, and AC = anterior capsule.

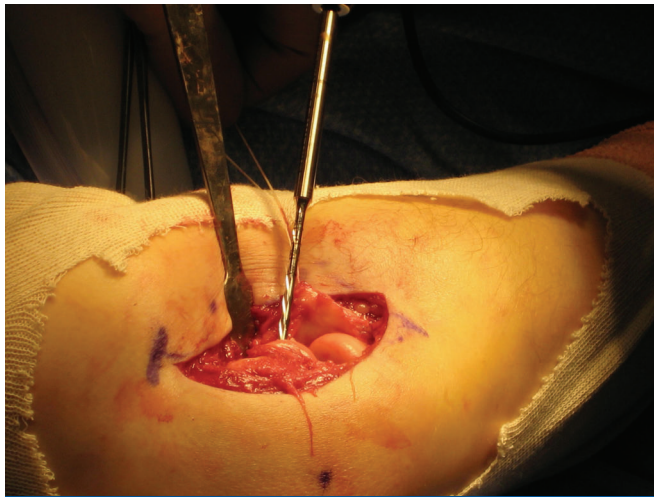


FIG. 5-C

Fig. 5-C A cannulated drill is inserted over each Kirschner wire. **Fig. 5-D** Headless cannulated screws are then inserted over the guidewires in an anterior-to-posterior direction. Fully threaded variable pitch mini-Acutrak headless screws (Acumed) were used in this patient.

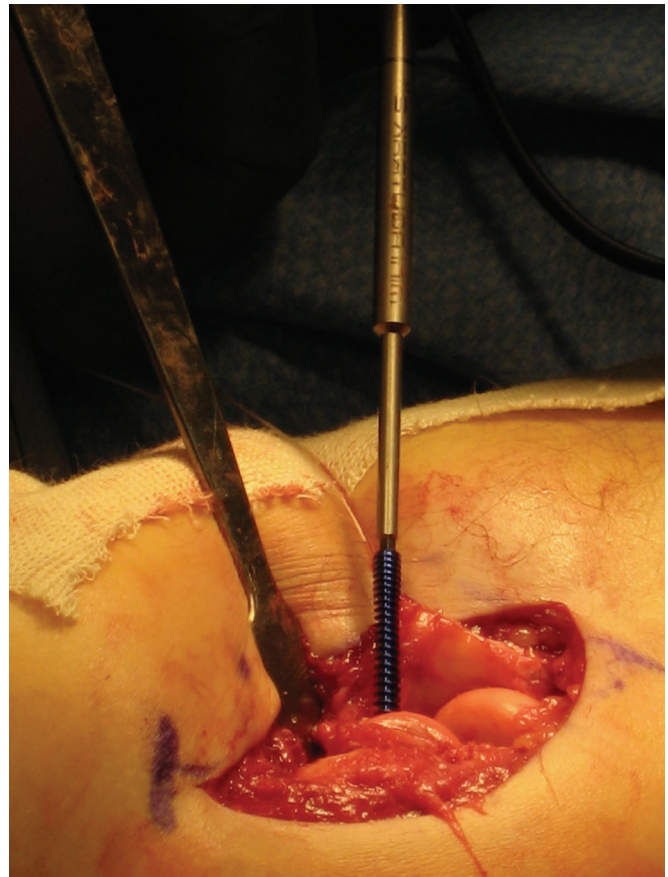
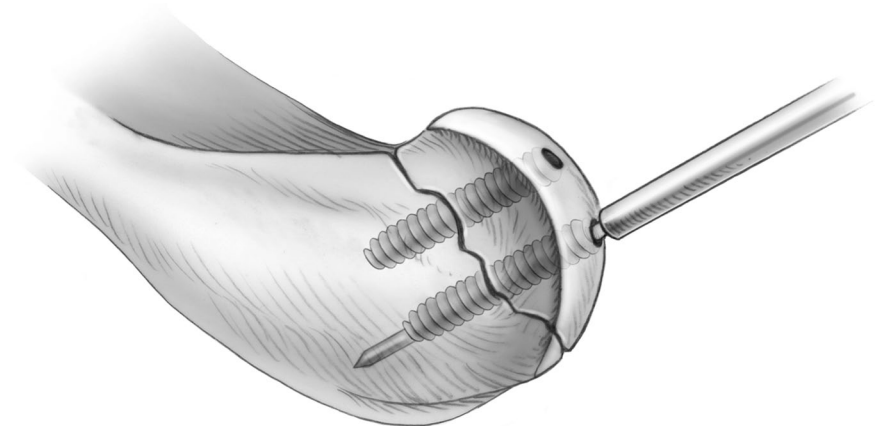
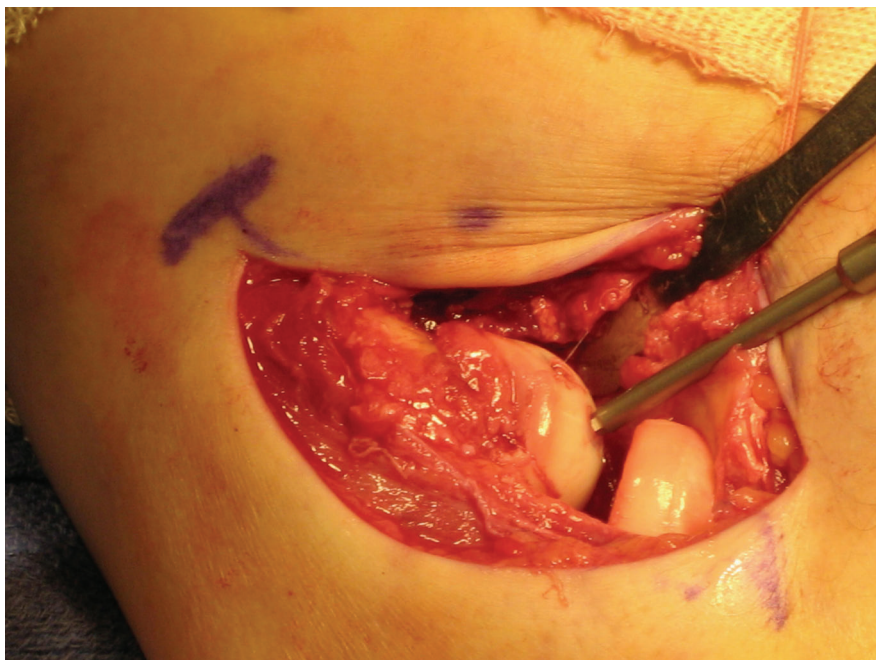


FIG. 5-D

**FIG. 5-E**

The screws are buried beneath the articular surface. The schematic shows buried fixation. (Reprinted, with permission, from: Ruchelsman DE, Teiwani NC, Kwon YW, Egol KA. Coronal plane partial articular fractures of the distal humerus: current concepts in management. JAAOS. 2008;16:716-28.)

posterior direction (Figs. 5-B through 5-E). The terminally threaded Herbert screw (Zimmer, Warsaw, Indiana) and fully threaded mini-Acutrak headless screw (Acumed, Hillsboro, Oregon) provide fracture site compression through variable thread pitch designs. A minimum of two screws are used in larger fragments to ensure rotational control (Figs. 6-A and 6-B). Care

is taken to spread the screws sufficiently to avoid iatrogenic fracture of the capitellum. The radial wrist extensors are repaired to the soft-tissue cuff on the lateral supracondylar ridge, and the Kocher interval is closed in continuity with the proximal exposure of the lateral column (Fig. 7). The remainder of the wound closure proceeds in a standard, layered fashion.

Supplemental fixation may be required to reconstruct more complex fracture patterns with posteroinferior-lateral metaphyseal comminution and/or trochlear extension (i.e., Type-III and IV fractures). Supplemental fixation options include minifragment screws, threaded Kirschner wires, and bioabsorbable pins for small (i.e., <5-mm) osteochondral capitellar-trochlear frag-

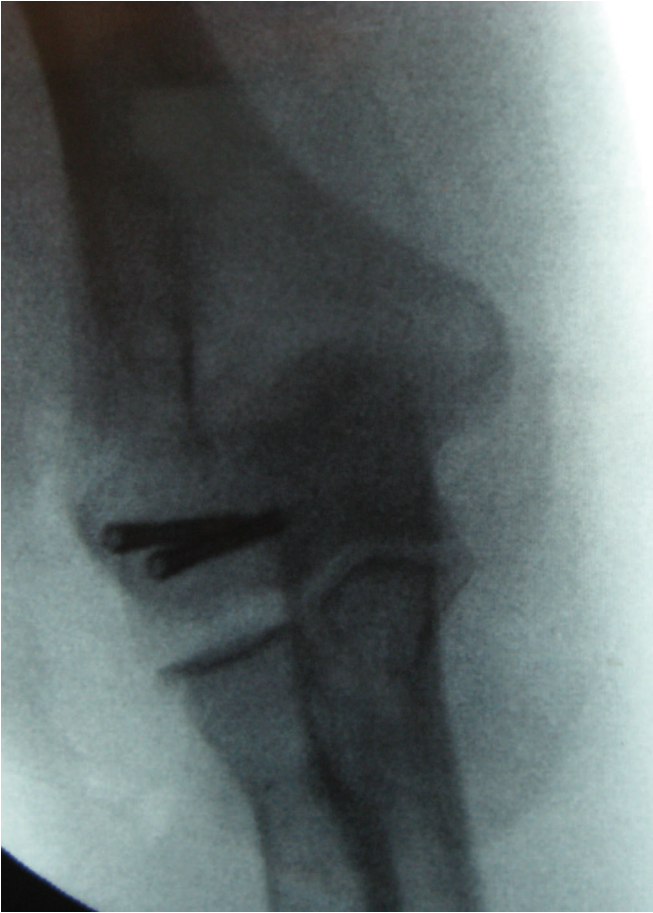

FIG. 6-A

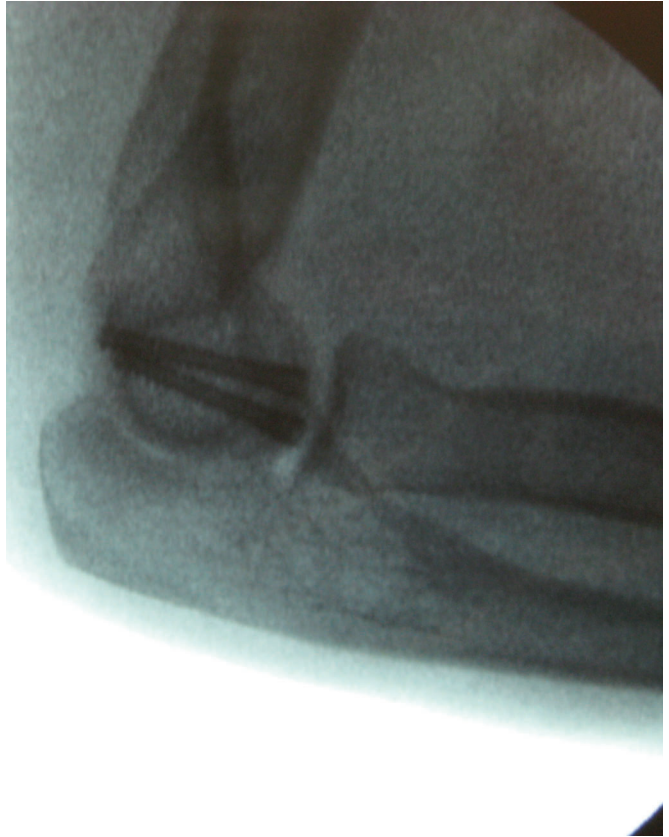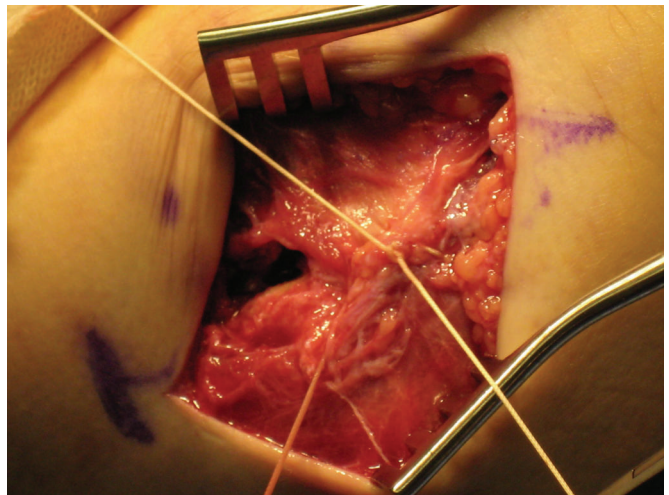


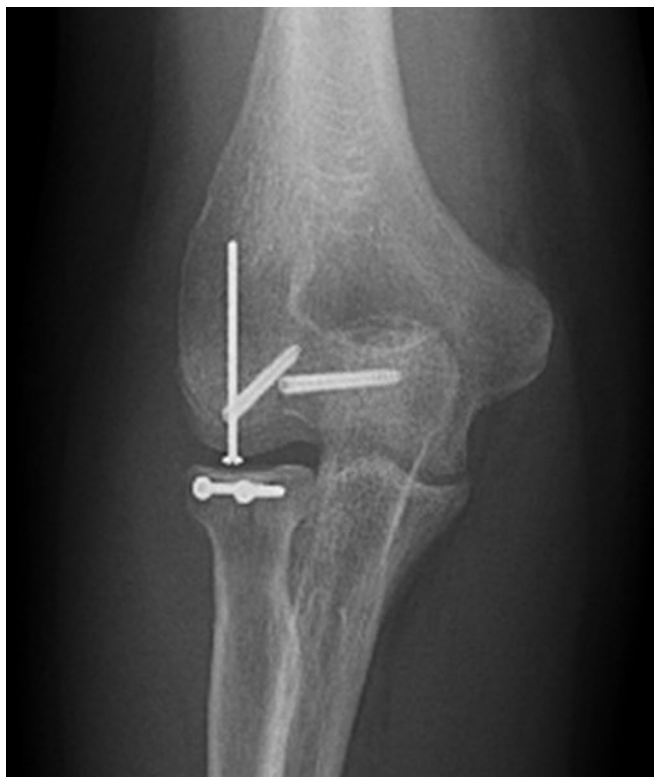FIG. 6-B

Final anteroposterior (Fig. 6-A) and lateral (Fig. 6-B) fluoroscopic images following fixation of a Type-IV² capitellar fracture.

FIG. 7

The radial wrist extensors are repaired to the soft-tissue cuff on the lateral supracondylar ridge. The Kocher interval is then closed in continuity with the lateral column exposure.



**FIG. 8**

Supplemental fixation construct in a Type-IV² fracture. A supplemental minifragment screw was placed from the inferolateral articular surface into the lateral column and was countersunk beneath the articular surface. Concomitant open reduction and internal fixation was performed for a displaced radial head fracture. (Reprinted, with permission, from: Ruchelsman DE, Tejwani NC, Kwon YW, Egol KA. Coronal plane partial articular fractures of the distal humerus: current concepts in management. *JAAOS*. 2008;16:716-28.)

ments. When there is extensive involvement of the lateral column or substantial posterolateral comminution, supplemental plate fixation with pelvic reconstruction, precontoured, or locking (i.e., fixed-angle) plates may be required to buttress the lateral column^{3,4,17}. When there is a concomitant radial head fracture, it is addressed through the same exposure (Fig. 8). When a lateral ulnar collateral ligament avulsion is identified or the lateral epicondyle fragment is too small to accept screw fixation, the lateral ulnar collateral liga-

ment is repaired primarily to its origin with use of suture anchors or transosseous sutures passed through drill-holes, or the fragment is secured with a figure-of-eight tension-band wire.

When rigid fixation has been achieved, a long arm posterior plaster splint and compressive dressing is applied with the elbow at approximately 90° of flexion. At the first office visit (i.e., seven to ten days postoperatively), the sutures are removed and active and active-assisted range of motion of the elbow and

forearm is initiated. Delayed or protected mobilization with a hinged functional elbow brace may be necessary when there is concern about the stability of fixation. A hinged brace with gradual reduction of the extension block facilitates maintenance of radial head congruity with the reduced capitellum. Static progressive extension thermoplastic splinting is used when a flexion contracture occurs in the early postoperative period. Strengthening exercises are initiated when there is clinical and radiographic evidence of fracture union.

CRITICAL CONCEPTS

INDICATIONS:

- Isolated displaced, capitellar-trochlear coronal-plane shear fractures of the distal humeral articular surface. These are relatively rare injuries.
- Capitellar-trochlear shear fractures occurring in association with complex distal humeral fractures and elbow fracture-dislocations with concomitant ligamentous injuries.

CONTRAINDICATIONS:

- There are no absolute contraindications to performing open reduction and internal fixation of capitellar fractures. If stable reconstruction of the articular surface cannot be achieved, total elbow arthroplasty may be considered in some elderly or osteoporotic patients. Total elbow arthroplasty represents a salvage option for severe symptomatic post-traumatic arthritis, articular osteonecrosis, nonunion or malunion, and elbow instability. Closed treatment with immobilization or fragment excision is only indicated in very select cases (i.e., a Type-II fracture).

PITFALLS:

- Underestimation of fracture complexity. The exact morphology of the fracture is often difficult to ascertain from preoperative plain radiographs alone. Computed tomographic images help to define the medial extent of the fracture, articular impaction, and metaphyseal and condylar comminution. Imaging must be carefully assessed for the presence of the “double arc” sign, representing medial trochlear extension, metaphyseal comminution, and radial head and/or neck pathology. Concomitant lateral and/or medial collateral ligament disruptions or their osseous functional equivalents must be recognized and repaired in order to restore elbow stability.
- Inadequate exposure of the radiocapitellar compartment and visualization of the trochlea and medial articular extension. Extensile surgical exposures and a variety of implants are required to address the more complex fracture patterns, which are characterized by metaphyseal comminution and ipsilateral radial head fracture, and often require supplemental fixation. On the basis of the fracture pattern, the surgeon should be prepared to perform a supplemental medial-based exposure—flexor-pronator split or elevation—when the medial aspect of the trochlea cannot be visualized from a lateral approach or when there is involvement of the medial column. A single posterior midline skin incision followed by elevation of full-thickness medial and lateral skin flaps and an olecranon osteotomy is indicated when trochlear comminution or extension of the articular fracture beyond the radiocapitellar compartment (i.e., a Ring Type-V fracture³ with medial epicondylar extension) is identified preoperatively.
- Failure to restore articular congruity.
- Potential for ulnohumeral instability if the trochlea-olecranon articulation is not restored.
- Failure to recognize posteroinferior metaphyseal comminution, which may require a cancellous allograft.
- Iatrogenic injuries to the posterior interosseous nerve.
- Iatrogenic injury to the lateral ulnar collateral ligament.
- Prolonged postoperative immobilization.

AUTHOR UPDATE:

There have been no changes in the surgical technique since publication of the original article.

David E. Ruchelsman, MD
Nirmal C. Tejwani, MD
Young W. Kwon, MD, PhD
Kenneth A. Egol, MD
Department of Orthopaedic Surgery, New York University Hospital for Joint Diseases, 301 East 17th Street, 14th Floor (D.E.R., N.C.T., and K.A.E.) and 4th Floor (Y.W.K.), New York, NY 10003. E-mail address for D.E. Ruchelsman: David.Ruchelsman@nyumc.org. E-mail address for N.C. Tejwani: Nirmal.Tejwani@nyumc.org. E-mail address for Y.W.

Kwon: Young.Kwon@nyumc.org. E-mail address for K.A. Egol: Kenneth.Egol@nyumc.org

The line drawings in this article are the work of Joanne Haderer Müller of Haderer & Müller (biomedart@haderermuller.com).

REFERENCES

1. Bryan RS, Morrey BF. Fractures of the distal humerus. In: Morrey BF, editor. The elbow

and its disorders. Philadelphia: Saunders; 1985. p 325-33.

2. McKee MD, Jupiter JB, Bamberger HB. Coronal shear fractures of the distal end of the humerus. J Bone Joint Surg Am. 1996;78:49-54.

3. Ring D, Jupiter JB, Gulotta L. Articular fractures of the distal part of the humerus. J Bone Joint Surg Am. 2003;85: 232-8.

- 4.** Dubberley JH, Faber KJ, Macdermid JC, Patterson SD, King GJ. Outcome after open reduction and internal fixation of capitellar and trochlear fractures. *J Bone Joint Surg Am.* 2006;88:46-54.
- 5.** Dushuttle RP, Coyle MP, Zawadsky JP, Bloom H. Fractures of the capitellum. *J Trauma.* 1985;25:317-21.
- 6.** Ma YZ, Zheng CB, Zhou TL, Yeh YC. Percutaneous probe reduction of frontal fractures of the humeral capitellum. *Clin Orthop Relat Res.* 1984;183:17-21.
- 7.** Ochner RS, Bloom H, Palumbo RC, Coyle MP. Closed reduction of coronal fractures of the capitellum. *J Trauma.* 1996;40:199-203.
- 8.** Grantham SA, Norris TR, Bush DC. Isolated fracture of the humeral capitellum. *Clin Orthop Relat Res.* 1981;161:262-9.
- 9.** Alvarez E, Patel MR, Nimberg G, Pearlman HS. Fracture of the capitulum humeri. *J Bone Joint Surg Am.* 1975;57:1093-6.
- 10.** Fowles JV, Kassab MT. Fracture of the capitulum humeri. Treatment by excision. *J Bone Joint Surg Am.* 1974;56:794-8.
- 11.** Ruchelsman DE, Tejwani NC, Kwon YW, Egol KA. Open reduction and internal fixation of capitellar fractures with headless screws. *J Bone Joint Surg Am.* 2008;90:1321-9.
- 12.** Goodman HJ, Choueka J. Complex coronal shear fractures of the distal humerus. *Bull Hosp Jt Dis.* 2005;62:85-9.
- 13.** Stamatis E, Paxinos O. The treatment and functional outcome of type IV coronal shear fractures of the distal humerus: a retrospective review of five cases. *J Orthop Trauma.* 2003;17:279-84.
- 14.** Sano S, Rokkaku T, Saito S, Tokunaga S, Abe Y, Moriya H. Herbert screw fixation of capitellar fractures. *J Shoulder Elbow Surg.* 2005;14:307-11.
- 15.** Imatani J, Morito Y, Hashizume H, Inoue H. Internal fixation for coronal shear fracture of the distal end of the humerus by the anterolateral approach. *J Shoulder Elbow Surg.* 2001;10:554-6.
- 16.** Mahirogullari M, Kiral A, Solakoglu C, Pehlivan O, Akmaz I, Rodop O. Treatment of fractures of the humeral capitellum using herbert screws. *J Hand Surg [Br].* 2006;31:320-5.
- 17.** Mighell MA, Harkins D, Klein D, Schneider S, Frankle M. Technique for internal fixation of capitellum and lateral trochlea fractures. *J Orthop Trauma.* 2006;20:699-704.