

# Adductor Pollicis Jamming Injuries in the Professional Baseball Player: 2 Case Reports

Grant G. Altobelli, MD, David E. Ruchelsman, MD, Mark R. Belsky, MD, Thomas Graham, MD, Peter Asnis, MD, Matthew I. Leibman, MD

We characterize a mechanism of injury, injury pattern, and treatment algorithm for adductor pollicis myotendinous injuries in 2 professional baseball players. Similar to myotendinous eccentric injuries in other anatomical areas, the adductor pollicis sustains a sudden forceful eccentric load during a jammed swing, resulting in intramuscular strain or tendon rupture. Based on the reported injury mechanism, and magnetic resonance imaging features of these myotendinous injuries, the thumb of the top hand during a jammed swing was suddenly and forcefully eccentrically abducted from a contracted and adducted position, resulting in injury patterns. (*J Hand Surg* 2013;38A:1181–1184. Copyright © 2013 by the American Society for Surgery of the Hand. All rights reserved.)

**Key words** Adductor pollicis, professional baseball.

THE ADDUCTOR POLLICIS muscle plays a key role in hand strength and function, especially for grip, pinch, and dynamic thumb metacarpophalangeal (MCP) joint stabilization.<sup>1</sup> Its roles in a variety of conditions have been well described.<sup>2–4</sup> Eccentric contraction has been described in other muscle injury patterns such as hamstring and biceps as a mechanism for both muscle strain and tendon rupture.<sup>5,6</sup> We report 2 cases of eccentric contraction of the adductor pollicis in professional baseball players, who call this a jammed thumb and that is sustained while swinging a bat.

The adductor pollicis, comprising transverse and oblique heads, adducts the thumb at the carpometacarpal joint. The transverse head originates primarily from the volar surface of the third metacarpal. The oblique head has a broad origin from the base of the second, third, and sometimes fourth metacarpals and from the volar deep carpal ligaments. The 2 heads converge in a

common tendinous insertion at the adductor tubercle on the ulnar base of the thumb proximal phalanx and on the ulnar sesamoid bone. The adductor aponeurosis overlies the ulnar aspect of the thumb MCP joint and contributes to the sagittal band and to dynamic stabilization of the MCP joint.<sup>7–10</sup>

Based on 8 years of observing professional baseball players, we surmise that sudden eccentric loading of the contracted adductor pollicis during a jammed swing causes intramuscular strain or rupture of the tendinous insertion. Key clinical features include first webspace swelling, ecchymosis, and tenderness, with the differential diagnosis including sagittal band and ulnar collateral ligament (UCL) injuries.

## CASE 1

A 31-year-old right-handed professional baseball player developed acute pain in his right thumb (top hand) and first webspace swelling after a self-described “jammed bat” mechanism while failing to make solid contact, which resulted in the bat being awkwardly jerked. He had experienced several similar jamming events over prior weeks with intermittent first webspace discomfort. Following the sentinel event, examination demonstrated marked swelling and ecchymosis in his first webspace without evidence of UCL disruption. Tenderness over the myotendinous junction of the adductor

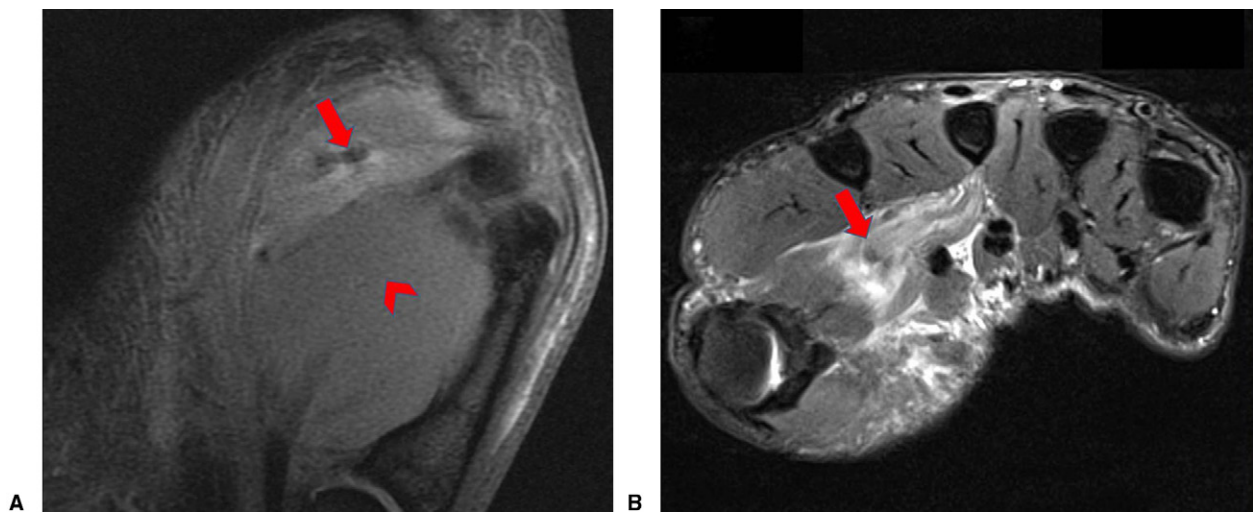
From the Department of Orthopaedic Surgery, Tufts Medical Center, Boston; Hand Surgery, P.C., Newton-Wellesley Hospital, Newton; Harvard Medical School, Boston, MA; and Department of Orthopaedic Surgery, Cleveland Clinic, Cleveland, Ohio.

Received for publication October 11, 2012; accepted in revised form March 21, 2013.

No benefits in any form have been received or will be received related directly or indirectly to the subject of this article.

**Corresponding author:** David E. Ruchelsman, MD, Hand Surgery, P.C., 2000 Washington St., Blue Building, Suite 201, Newton, MA 02462; e-mail: druchelsman@partners.org.

0363-5023/13/38A06-0019\$36.00/0  
<http://dx.doi.org/10.1016/j.jhssa.2013.03.042>



**FIGURE 1:** Right hand of a 31-year-old baseball player with multiple jamming events culminating in an event that resulted in acute pain and swelling in the first webpace. **A** Coronal magnetic resonance imaging (MRI) scan demonstrates a retracted tear of the transverse head of the adductor pollicis muscle (arrow) and intact transverse head (arrowhead). **B** Axial MRI scan demonstrates a retracted tear of the transverse head of the adductor pollicis (arrow).

was coupled with discomfort during resisted thumb adduction.

Radiographs were unremarkable for fractures or avulsions. Magnetic resonance imaging (MRI) revealed a complete tear of the transverse head of the adductor pollicis muscle with 2 cm of retraction into the palm (Fig. 1). Hematoma throughout the adductor pollicis muscle belly was seen. The oblique head of the adductor pollicis was intact. No bony edema was present, and the MCP joint, UCL, and volar plate were intact.

The retraction of the tendon created concern that grip strength would be markedly compromised if allowed to heal in a nonanatomical position. Intraoperatively, a cuff of the adductor aponeurosis was attached to the retracted tendon. The UCL and volar plate were both intact. The transverse head of the adductor was reattached to its insertion using nonabsorbable suture.

A forearm-based thumb spica orthosis with the interphalangeal joint free was used for 3 weeks, then transitioned to a hand-based thumb spica orthosis for an additional 3 weeks. Active thumb motion was started 6 weeks after surgery and thenar strengthening at 12 weeks. The patient was cleared to return to all baseball activities 4 months after surgery, after which he made a full recovery to his preinjury level of performance.

## CASE 2

A 29-year-old right-handed professional baseball player presented with an identical history and mechanism of injury as Case 1. Over a 3-week period, the player sustained multiple jamming events that resulted in pain and swelling in the first webpace of his top hand (right

hand). In this case, we had the opportunity to evaluate the injury immediately after 2 nondisabling events.

Subtle ecchymosis and mild tenderness in the first webpace and ulnar aspect of the thumb MCP joint were noted. There was no laxity or instability of the thumb MCP joint, and adduction of his thumb against resistance was painless.

He continued to play using tape around his thumb. He then sustained a major jamming event that resulted in severe pain and precluded continued play. This episode was 4 weeks after his initial injury and resulted in noteworthy swelling, ecchymosis, and tenderness in the first webpace. The thumb MCP joint remained nontender and stable.

An MRI of the thumb demonstrated a midsubstance tear of the transverse head of the adductor pollicis. The UCL and thumb MCP joint showed no abnormality.

Nonsurgical management was recommended owing to the midsubstance nature of the injury. A 3-week course of immobilization in a custom-molded thermoplastic thumb spica orthosis was recommended. The player elected to play after 10 days with a custom batting orthosis despite persistent discomfort and limited grip strength. The splint was designed to pad the first web against the bat and simultaneously to prevent forced abduction during a jamming event (Fig. 2). The player switched to a lighter bat that was more prone to breaking at its shaft if he jammed it. Protected play was discontinued when the patient was pain free at 6 weeks. A follow-up MRI of his hand at 6 weeks demonstrated healing of the adductor pollicis. He subsequently returned to his preinjury level of performance.



**FIGURE 2:** Custom orthosis designed to pad the first webspace (white flexible material) and prevent forced abduction of the thumb (black rigid material).

## DISCUSSION

Baseball players frequently characterize a late swing on an inside pitch as being “jammed.” We describe 2 cases in which professional baseball players had discrete injuries noted at the time of impact while getting “jammed.” Much like the well-accepted mechanism of injury of the hamstrings and distal biceps, we surmise sudden eccentric loading of the adductor pollicis creates tendon rupture or midsubstance muscle injury. Multiple factors including timing of swing, location of pitch, position of hand at time of impact, and type of bat will influence the spectrum of thumb injuries seen.

In the professional baseball swing, the top forearm begins in a near-neutral position, progressing to relative supination with the initiation of the swing, and transitioning to pronation during follow-through. With the location of the pitch and timing of the swing being highly dynamic, the position of the hand relative to the bat is quite variable. Although in the majority of swings the force transmission from the bat handle to the hand occurs through the palm, this is likely not the case when the batter gets jammed. Unlike a typical swing, in a jammed swing the batter maintains his top forearm in

supination, resulting in the bat handle shifting from the palm toward the base of the thumb. This may be attributed to factors such as an inside pitch preventing arm extension or a delayed swing. Force applied through the bat handle to the base of the thumb therefore causes a sudden abduction force during an eccentric contraction of the adductor pollicis. As with other injuries to the muscle-tendon unit during eccentric contraction, the injury patterns from the jammed swing include intramuscular strain and rupture of the tendinous insertion.

The type of bat may also affect the force transmitted to the thumb in a jammed swing. In professional baseball, common bat materials include maple, birch, and ash, providing variability in surface hardness, density, flexibility, durability, grain density, and brittleness. These qualities affect performance and may contribute to injury potential because a stiffer bat will absorb less energy and transmit more force to a hand in a potentially compromised position.

Both players presented with a prodrome of 3 to 4 weeks of jamming events with vague thumb and radial-sided wrist pain. They were able to play through the pain initially. Early examination was nonspecific with negative x-rays. Both players sustained an acute jam that occurred following the prodrome that resulted in an inability to continue playing. Examination demonstrated swelling, ecchymosis, and tenderness localized to the first webspace and minimal to no osseous or ligamentous tenderness, key features of the clinical diagnosis. An MRI may confirm this diagnosis and help define the injury pattern as a midsubstance tear or tendon avulsion-type injury.

In professional baseball players, maintaining maximal grip strength is paramount. Although rare for the hand surgeon to be involved during the prodrome period, we recommend conservative management with functional splinting. If the adductor pollicis is avulsed at the tendinous junction, we recommend immediate direct surgical repair in order to restore the anatomy of the adductor pollicis, a key contributor to grip strength. However, when treating a midsubstance tear that is not amenable to surgical repair, we recommend a 3- to 4-week course of hand-based immobilization in a thumb spica orthosis.

It remains to be seen whether treatment during the prodrome can avoid subsequent rupture. These cases serve to highlight a likely underrecognized injury mechanism and pattern.

## REFERENCES

1. Kozin S, Porter S, Clark P, Thoder J. The contribution of the intrinsic muscles to grip and pinch strength. *J Hand Surg Am.* 1999;24(1):64–72.

2. Ruder JR, Wood VE. Ulnar nerve compression at the arch of the origin of the adductor pollicis. *J Hand Surg Am.* 1993;18(5):893–895.
3. Chen VT. Haemangioma of adductor pollicis. *Hand.* 1977;9(2):187–194.
4. Stener B. Displacement of the ruptured ulnar collateral ligament of the metacarpophalangeal joint of the thumb. *J Bone Joint Surg Br.* 1962;44(4):869–879.
5. Opar DA, Williams MD, Shield AJ. Hamstring strain injuries: factors that lead to injury and re-injury. *Sports Med.* 2012;42(3):209–226.
6. Ramsey M. Distal biceps tendon injuries: diagnosis and management. *J Am Acad Orthop Surg.* 1999;7(3):199–207.
7. Witthaut J, Leclercq C. Anatomy of the adductor pollicis muscle, a basis for release procedures for adduction contractures of the thumb. *J Hand Surg Br.* 1998;23(3):380–383.
8. Chang L, Blair WF. The origin and innervation of the adductor pollicis muscle. *J Anat.* 1985;140(3):381–388.
9. Jaibaji M, Rayan GM, Chung KW. Functional anatomy of the thumb sagittal band. *J Hand Surg Am.* 2008;33(6):879–884.
10. Mardel S, Underwood M. Adductor pollicis—the missing interosseous. *Surg Radiol Anat.* 1991;13(1):49–52.