



# American Society for Surgery of the Hand

## Basic Hand Anatomy

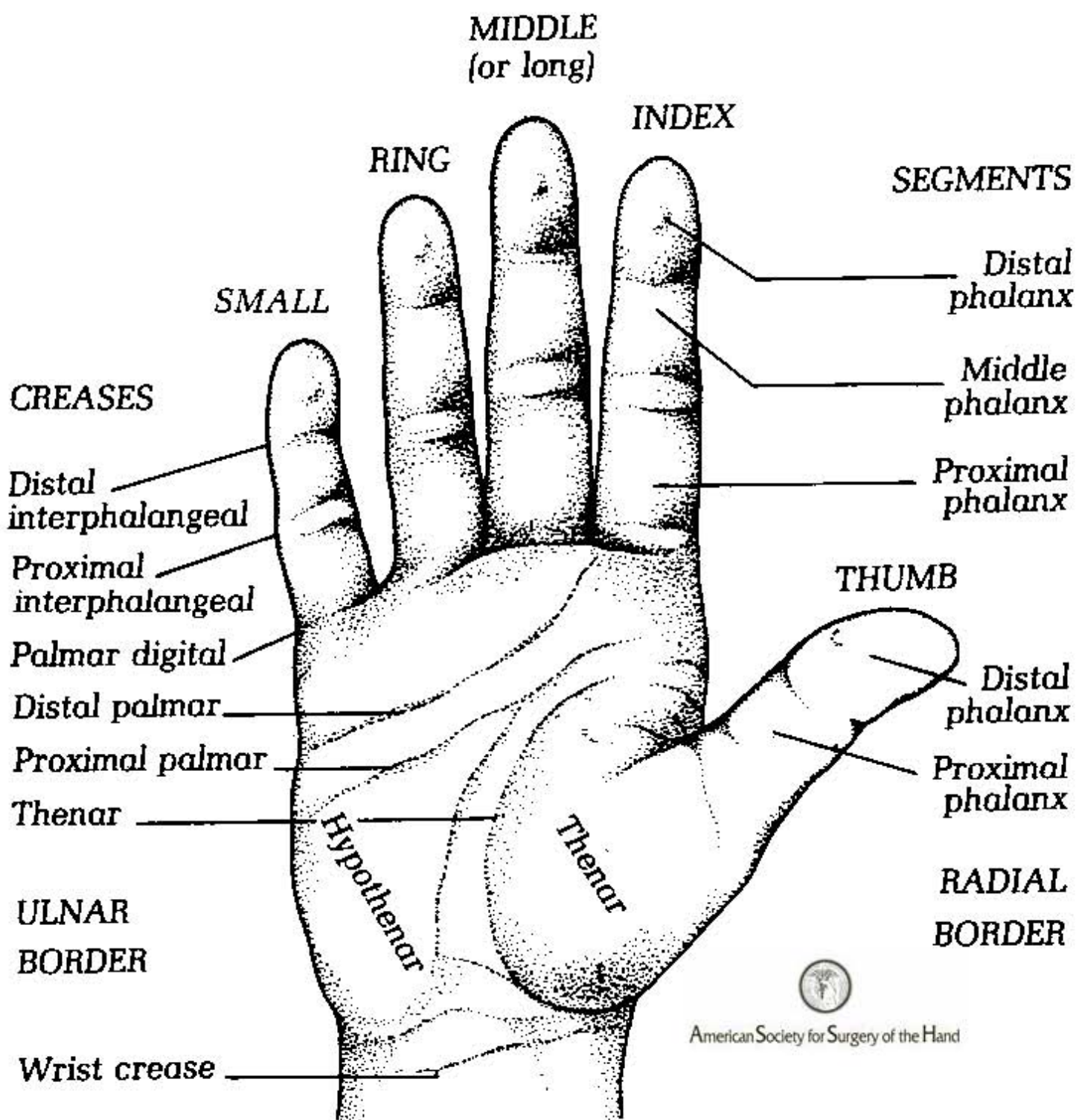
[Surface Anatomy](#)  
[Joints and Bones](#)  
[Fingertip Anatomy](#)  
[Motion.A](#)  
[Motion.B](#)

Images from *The Hand: Examination and Diagnosis*, 3<sup>rd</sup> Edition  
Written by American Society for Surgery of the Hand  
Published by Churchill Livingstone

No part of these images may be reproduced or presented without expressed written consent of the American Society for Surgery of the Hand.

# SURFACE ANATOMY

(Palmar surface)



# JOINTS

Distal interphalangeal (DIP)

Proximal interphalangeal (PIP)

Metacarpophalangeal (MCP)

# BONES

Interphalangeal

Metacarpophalangeal

Carpometacarpal (basilar joint)

Distal phalanges

Middle phalanges

Proximal phalanges

Metacarpals

Hamate

Pisiform

Triquetrum

Capitate

Lunate

Trapezoid

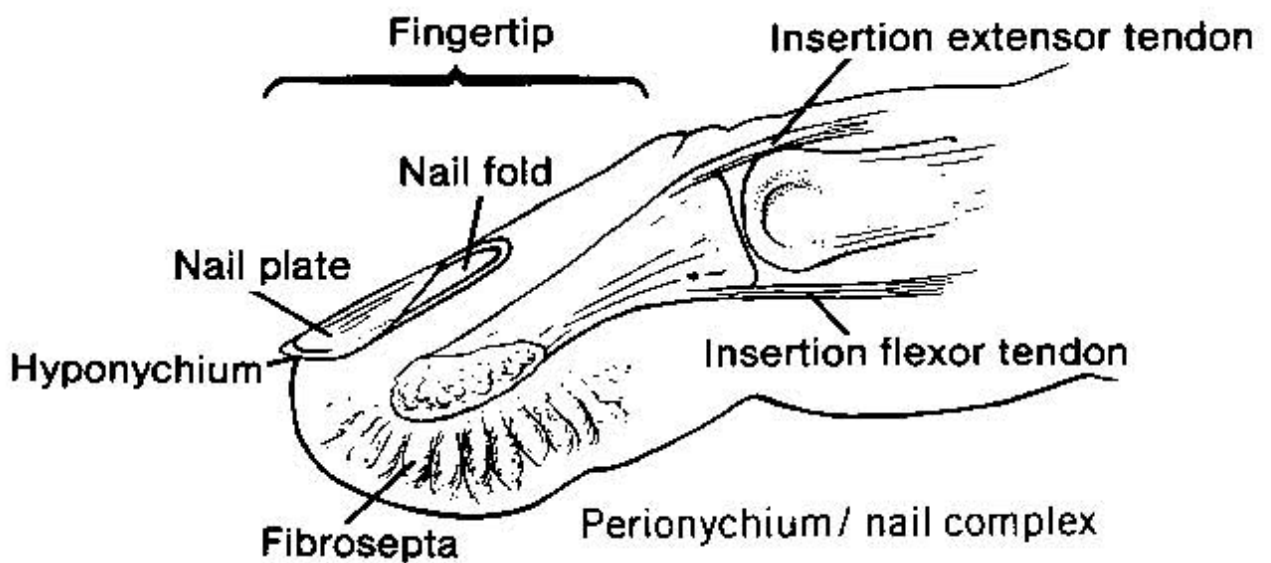
Trapezium

Scaphoid

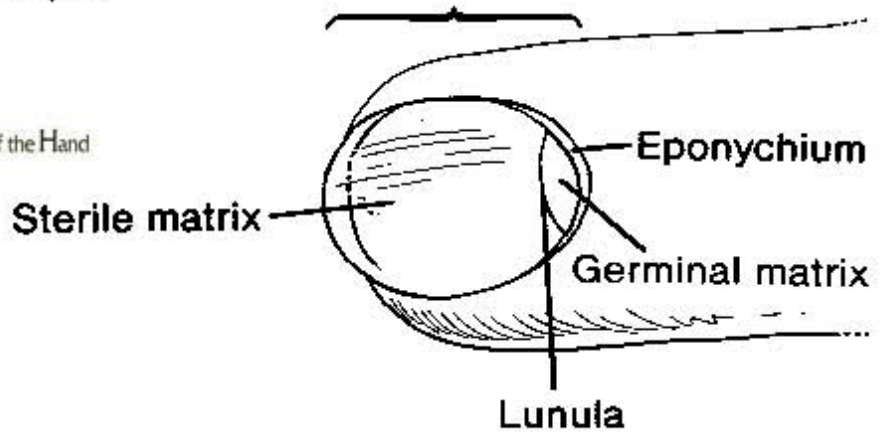


American Society for Surgery of the Hand

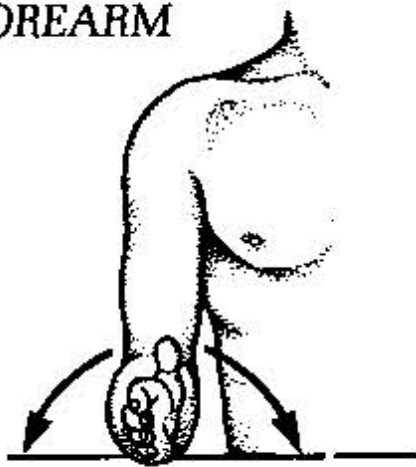
## FINGERTIP AND NAIL COMPLEX



American Society for Surgery of the Hand



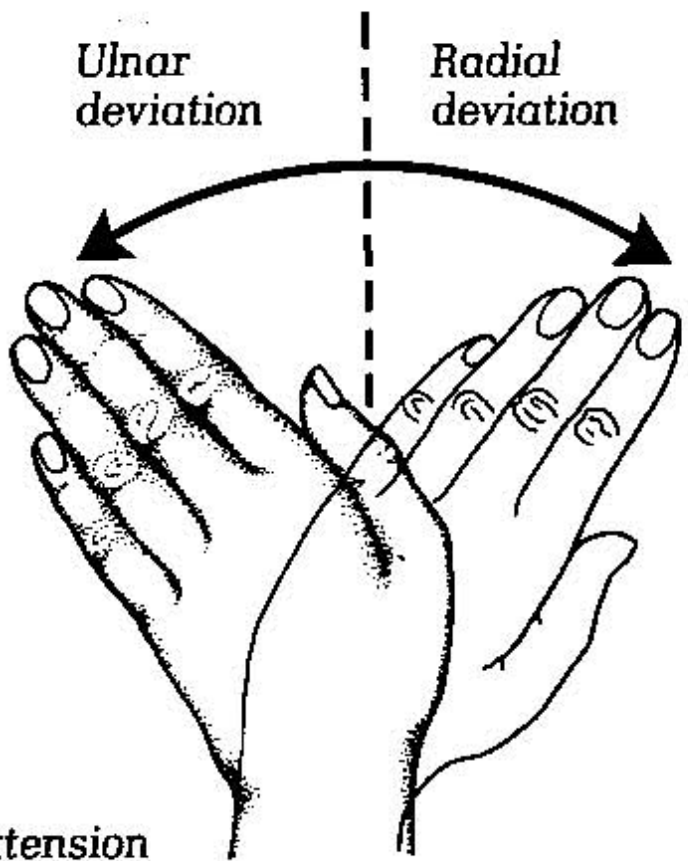
**FOREARM**



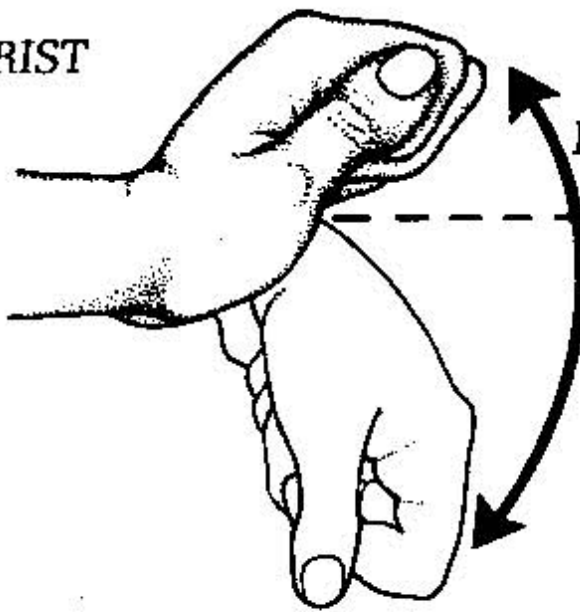
Supination      Pronation

Ulnar deviation

Radial deviation



**WRIST**



Extension

Flexion

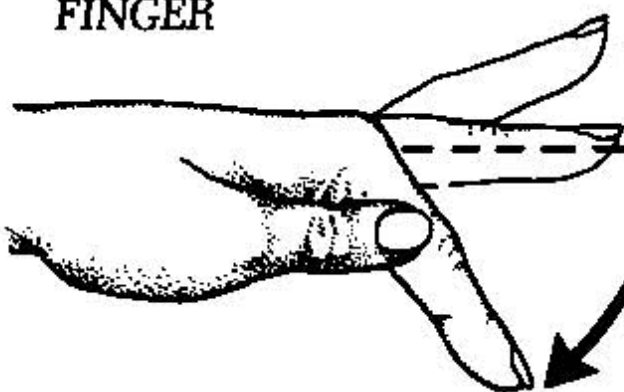


American Society for Surgery of the Hand

Abduction

Adduction

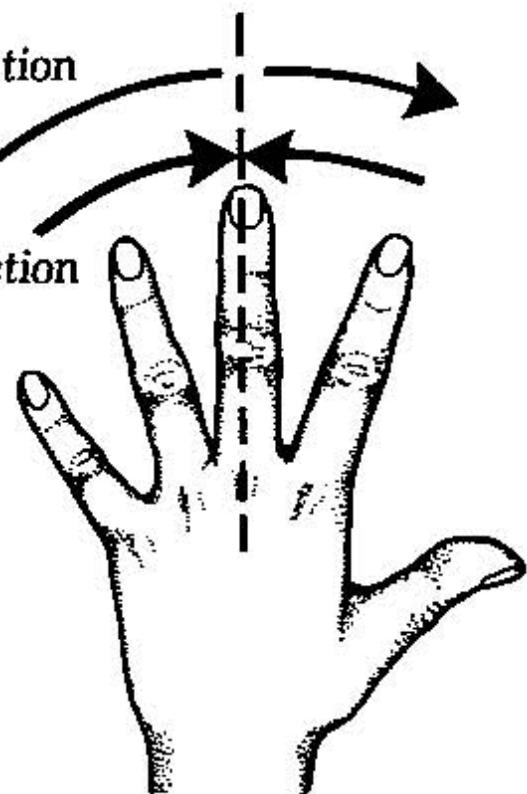
**FINGER**

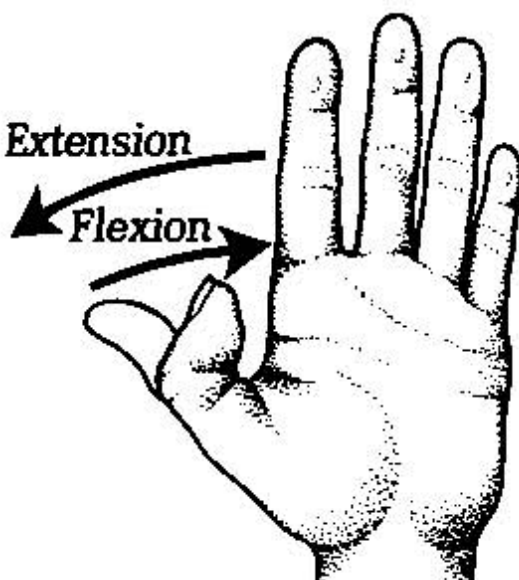


Hyper-extension

Extension

Flexion



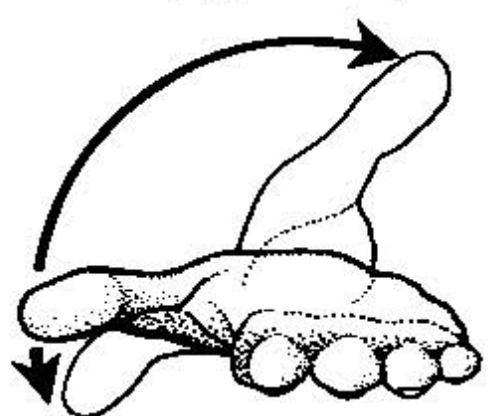
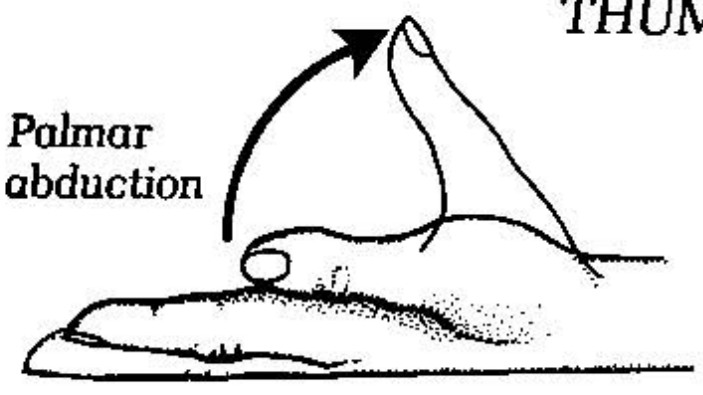


Opposing thumb to finger

Anteposition (opposition)

**THUMB**

Palmar abduction

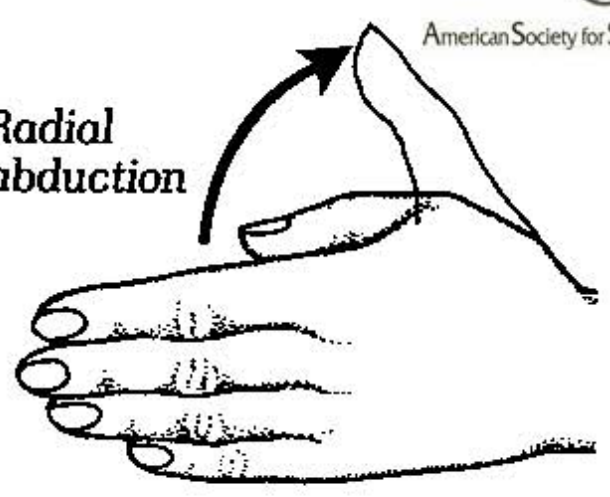


Retroposition



American Society for Surgery of the Hand

Radial abduction



Palmar abduction

Anteposition (opposition)

